RadioGraphics

Transvaginal US after Bowel Preparation for Deeply Infiltrating Endometriosis: Protocol, Imaging Appearances, and Laparoscopic Correlation[1]

ONLINE-ONLY CME

See www.rsna.org/education/rg_cme.html

LEARNING OBJECTIVES

After reading this article and taking the test, the reader will be able to:

- Discuss the role of transvaginal US performed after bowel preparation in evaluating patients with suspected endometriosis.
- Describe adequate preimaging preparation of patients with suspected endometriosis.
- Identify the typical findings of deeply infiltrating endometriosis at transvaginal US performed after bowel preparation.

TEACHING POINTS

See last page

Luciana Pardini Chamié, MD, PhD • Ricardo Mendes Alves Pereira, MD
Alysson Zanatta, MD • Paulo Cesar Serafini, MD, PhD

Deeply infiltrating endometriosis (DIE) is a common gynecologic disease that is characterized by a difficult and delayed diagnosis. Radiologic mapping of the DIE lesion sites is crucial for case management, patient counseling, and surgical planning. Transvaginal ultrasonography (US) is the initial imaging modality for investigating DIE and has been the focus of several recent studies. DIE typically manifests at imaging as hypoechogenic nodules throughout the affected sites and thickening of the intestinal wall, with some lesions showing a mixed pattern due to cystic areas. Transvaginal US performed after bowel preparation improves the ability to diagnose intestinal lesions and provides invaluable details, including which layers of the intestine are affected and the distance between the lesion and the anal border. It is vital that radiologists be familiar with the technical aspects of this modality and with the US manifestations of DIE lesions. Transvaginal US performed after bowel preparation should be the first-line imaging modality for the evaluation of women with suspected endometriosis.

Abbreviations: DIE = deeply infiltrating endometriosis, USL = uterosacral ligament

RadioGraphics 2010; 30:1235–1249 • **Published online** 10.1148/rg.305095221 • **Content Codes:** GU OB US

[1]From the Department of Diagnostic Imaging, Fleury Medicina e Saúde, Rua Cincinato Braga, 232, São Paulo 01333-910, Brazil (L.P.C.); Huntington Medicina Reprodutiva, São Paulo, Brazil (R.M.A.P., A.Z., P.C.S.); and Division of Human Reproduction, Department of Gynecology, Faculdade de Medicina da Universidade de São Paulo, São Paulo, Brazil (P.C.S.). Received December 8, 2009; revision requested January 18, 2010 and received March 9; accepted March 10. For this CME activity, the authors, editors, and reviewers have no relevant relationships to disclose. **Address correspondence to** L.P.C. (e-mail: *luciana.chamie@fleury.com.br*).

Introduction

Deeply infiltrating endometriosis (DIE) is a prevalent gynecologic disease characterized by multifocal lesions that penetrate below the surface of the pelvic peritoneum (1). Clinical presentation includes dysmenorrhea, dyspareunia, dyschezia, and infertility, but the diagnosis of DIE is difficult and can be delayed (2). The deeply infiltrating lesions seen in patients with DIE cause chronic and more painful symptoms than those caused by superficial lesions (3). Routine clinical examination is insufficient for the diagnosis and the evaluation of the extent of DIE (4).

At histologic analysis, DIE lesions differ significantly from ovarian and superficial peritoneal lesions. In DIE lesions, there is typically a striking proliferation of the indigenous smooth muscle that surrounds foci of endometriosis, often resulting in a firm, solid, tumorlike mass that extends more than 5 mm from the peritoneal surface into adjacent structures, often with associated fibrotic reaction (1). Imaging findings reflect the predominant smooth muscle proliferation and the fibrotic component (5).

In the past 10 years, DIE has gained increasing attention from radiologists, resulting in the publication of several studies, most of which emphasize the value of either transvaginal ultrasonography (US) or magnetic resonance (MR) imaging for the preoperative mapping of endometriotic implants (6–9). Adequate assessment of the endometriotic lesions is of major importance, not only for reducing diagnostic delay but also for allowing the clinician to discuss and plan appropriate surgical treatment and to obtain informed consent.

Teaching Point

Transvaginal US is a more accessible and widespread method of pelvic imaging and is the initial imaging modality for evaluating patients with suspected endometriosis (10,11). Despite the lack of prospective studies evaluating the usefulness of this method for diagnosing DIE, several authors have obtained excellent results in depicting endometriotic implants in the bladder (accuracy, 100%), retrocervical area (accuracy, 77%–97%), and rectosigmoid colon (accuracy, ≥95%) (7,9,12–15). The diagnosis of intestinal lesions was improved by adding a bowel preparation or using water as a contrast agent in the rectum. These techniques provide supplementary data on the intestinal layers affected and the distance from the lesion to the anal border, information that is very useful for surgical planning (9,16–18). Recently, we demonstrated a high accuracy (100%) for transvaginal US after bowel preparation in estimating the distance between the anal border and rectosigmoid lesions less than 11 cm away (16). In women with lesions more than 11 cm from the anal border, the accuracy was 75% (16). The major surgical implication is the risk of complications for gastrointestinal anastomosis (eg, rectovaginal fistulas) performed below the peritoneal reflection, especially in the lower rectum (<5 cm from the anal border).

MR imaging is commonly used for preoperative evaluation of endometriotic lesions and is considered the best noninvasive modality in this setting, providing a more reliable map of DIE lesions than does physical examination or transvaginal US. In a recent study of 92 patients (8), MR imaging demonstrated high accuracy in depicting DIE in the retrocervical space (90.2%), rectosigmoid colon (89.1%), bladder (89.1%), and ureters (95.7%), findings that were similar to those in other studies (6,7,13,19). Although excellent results were obtained with these studies, MR imaging is expensive, time consuming, and not widely available. Moreover, recently published data show a high accuracy for transvaginal US performed after bowel preparation in depicting multiple intestinal lesions and identifying the intestinal layers affected (9). Real-time, high-resolution transvaginal US performed after bowel preparation is, in fact, superior to MR imaging in this context, allowing evaluation of the entire rectosigmoid colon in the majority of women and reducing the likelihood of peristaltic artifacts and redundant bowel segments, which may complicate the analysis.

Regardless of the protocol used, identifying endometriotic implants with transvaginal US requires an experienced radiologist with a knowledge of the pelvic anatomy and of the morphologic peculiarities of this complex disease. The learning curve is an important issue to consider, and adequate interaction with the gynecologist is fundamental. Fortunately, DIE lesions have a somewhat predictable distribution in the pelvic cavity, which facilitates the investigation. The most commonly affected sites are the retrocervical area, rectosigmoid colon, vagina, and bladder (20,21).

In this article, we describe our protocol for transvaginal US performed after bowel preparation and discuss and illustrate the typical imaging findings of DIE in multiple pelvic sites with laparoscopic correlation.

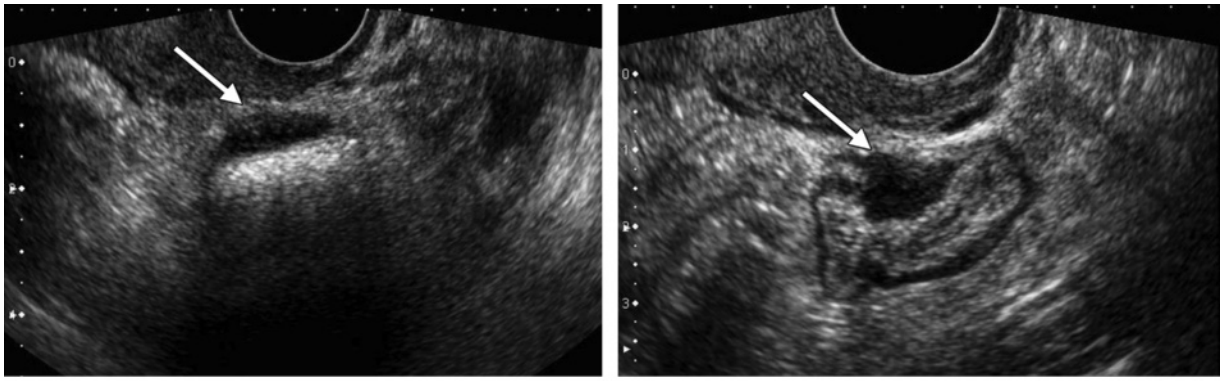

a. b.

Figure 1. Transvaginal US images obtained in a 30-year-old woman before **(a)** and after **(b)** bowel preparation show a DIE lesion (arrow) attached to the rectal wall. The affected layers (serosa and internal muscularis propria) and the margins of the lesion are more clearly visible after bowel cleansing.

Imaging Protocol

Bowel Preparation

Teaching Point

Bowel preparation is used to eliminate fecal residues and gas in the rectosigmoid colon (Fig 1) and is accomplished by administering *(a)* a mild laxative orally at 8:00 AM and 2:00 PM the day before the transvaginal US examination, *(b)* a low-residue diet on the day before and the day of the examination, and *(c)* a rectal enema consisting of 120 mL of sodium diphosphate approximately 1 hour prior to the examination.

Transvaginal US

Teaching Point

After bowel preparation, transvaginal US is performed with a 5–9-MHz transducer. It is used to evaluate the uterus and ovaries as well as the pelvic peritoneum, which includes the bladder, vesicouterine pouch, pouch of Douglas, retrocervical space, rectovaginal septum, and posterior vaginal fornix. The rectosigmoid colon is also evaluated from the anal verge to the sigmoid-descending colon transition by rotating the probe in the axial and sagittal planes in addition to moving the probe up and down. After being introduced transvaginally, the transducer is maintained at an angle of 45°, and the rectum (lower, middle, and upper) is examined, followed by examination of the sigmoid colon as far as possible. The assessment must be completed with a transabdominal evaluation of the descending colon, appendix, and ileocecal transition made with a linear transducer because these regions may be inaccessible transvaginally. The bowel preparation allows transabdominal assessment of these segments with good resolution and no patient discomfort.

To evaluate the insertion of the uterosacral ligaments (USLs) in the retrocervical space, an axial image of the cervix is obtained, followed by rotation of the probe in the right and left sagittal oblique planes in addition to moving the probe up and down.

With respect to intestinal lesions, the examination must include determination of the bowel layers and circumference affected as well as the distance from the anal verge. The latter can be estimated by measuring the distance between the peritoneal reflection (7–9 cm from the anal verge) and the bowel lesion. To estimate the percentage of the circumference affected, an axial view is required, on which the bowel is separated into four quadrants. The application of US gel in the posterior vaginal fornix allows the examiner to differentiate between adherent and infiltrating lesions.

For examination of the anterior compartment, the transducer is angled toward the os pubis and then moved to obtain the sagittal and axial views. The posterior bladder dome and the anterior uterine serosa should be examined carefully.

With transvaginal US, the examiner can also search for adhesions among the uterus, ovaries, and intestinal loops by moving the transducer backward and forward to assess whether these structures slip over each other. This maneuver is combined with abdominal palpation.

All lesions are measured in three directions (anteroposterior, longitudinal, and transverse), or in the longest axis if possible.

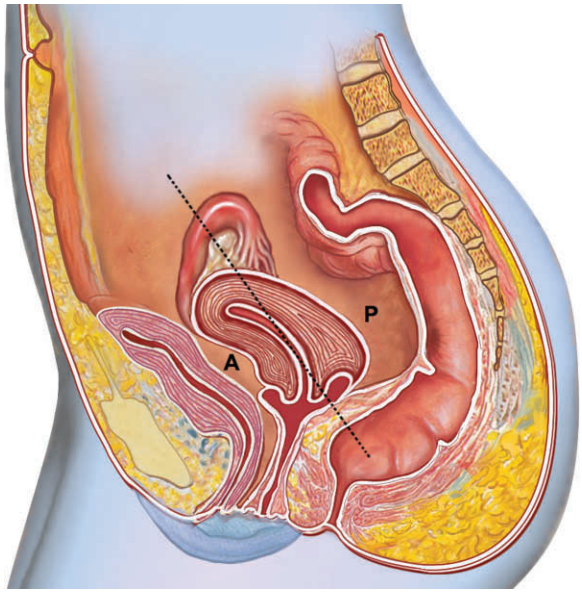

Figure 2. Drawing (midsagittal view) illustrates the female pelvis. Dotted line separates the pelvis into anterior *(A)* and posterior *(P)* compartments.

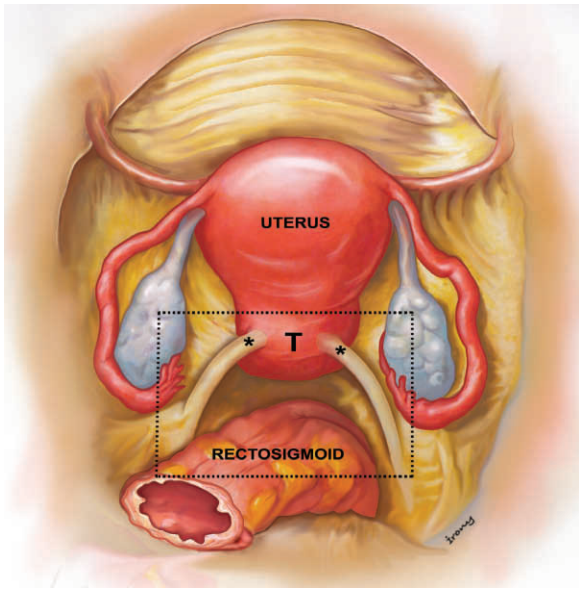

Figure 3. Drawing illustrates the posterior compartment of the female pelvis. Box indicates the retrocervical space, which includes the uterine torus *(T)*, USLs (*), rectosigmoid colon, and pouch of Douglas.

Anatomic Considerations

The investigation of endometriotic implants and the description of imaging findings must be guided by an algorithm that is based on the anatomic distribution of the disease. To facilitate mapping of the DIE lesions, the pelvic cavity is separated into two compartments: anterior and posterior (Fig 2).

The anterior compartment is the region between the anterior pelvic wall and the anterior uterine serosa. The sites potentially affected in this area are *(a)* the posterior bladder dome, typically in the midline; *(b)* the anterior uterine serosa, from the transition of the cervical isthmus to the uterine fundus; and *(c)* the uterine insertion of the round ligaments.

The posterior compartment is the region between the posterior uterine serosa and the presacral space (Fig 3). It is frequently affected by DIE and consists of *(a)* the retrocervical space, which also includes the uterine torus and USLs; *(b)* the rectosigmoid colon; *(c)* the rectovaginal area; and *(d)* the posterior vaginal fornix.

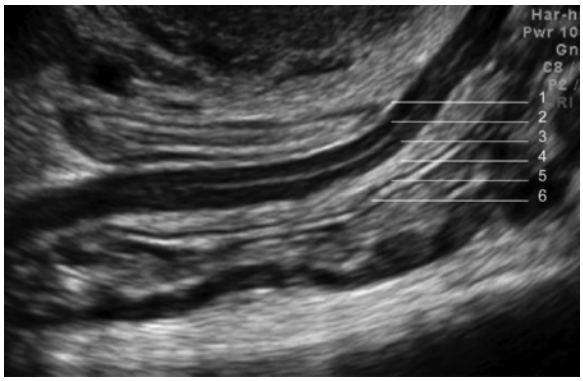

Figure 4. Sagittal transvaginal US image of the normal rectum obtained after bowel preparation shows (from the outer layer to the inner layer) the serosa *(1)*, external muscularis propria *(2)*, internal muscularis propria *(3)*, submucosa *(4)*, muscularis mucosa *(5)*, and mucosa *(6)*.

Teaching Point

It is important that the examiner have a knowledge of the normal appearance of the intestinal wall at transvaginal US performed after bowel preparation. The bowel wall is composed of different layers, each of which has a typical appearance at this imaging modality. These layers include the serosa (thin hyperechoic line), the muscularis propria (two hypoechoic strips separated by a thin hyperechoic line), the submucosa (hyperechoic), the muscularis mucosa (hypoechoic), and the interface between the lumen and the mucosal layer (hyperechoic) (Fig 4).

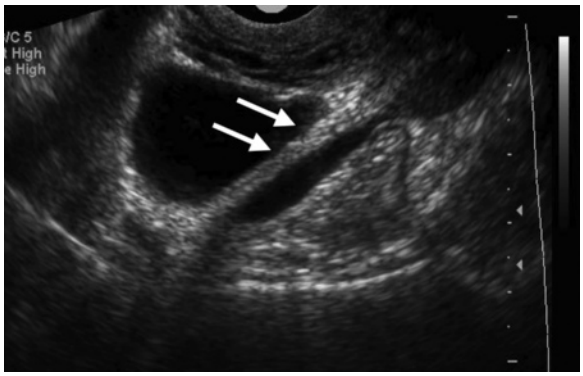

Figure 5. On an axial transvaginal US image obtained in a 34-year-old woman after bowel preparation, identification of the normal right USL (arrows) is facilitated by a small amount of fluid surrounding the ligament. The USL is hyperechogenic and 2–3 mm thick.

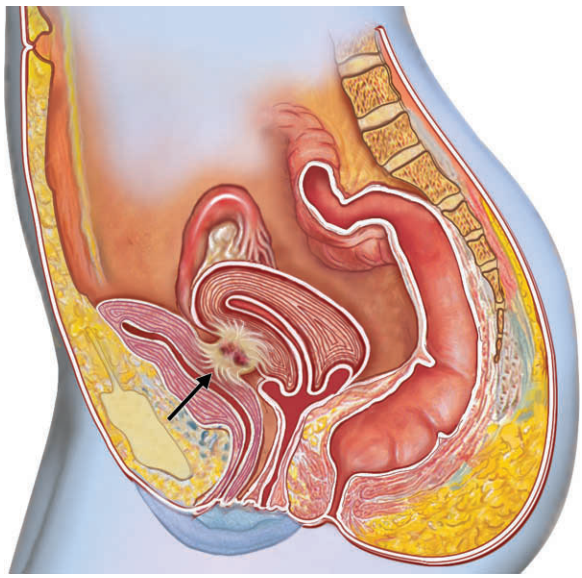

Figure 6. Drawing (midsagittal view) of the female pelvis shows a mixed endometriotic nodule (solid with hemorrhagic areas) (arrow) that is attached to the posterior bladder wall and the anterior uterine serosa.

A normal USL is difficult to see, except in cases in which liquid in the pouch of Douglas surrounds its insertion (Fig 5). The USLs are hyperechogenic and measure 2–3 mm in thickness.

The rectovaginal area corresponds to the posterior region situated between the superior and middle third of the vagina and rectum, under the peritoneal reflection. The inferior third of this region is the rectovaginal septum, which is not affected in the majority of patients.

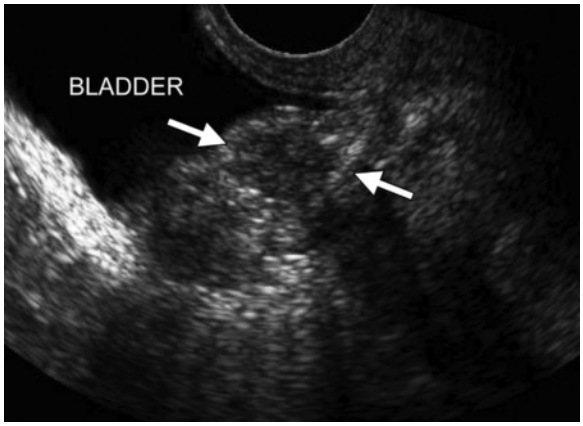

Figure 7. Bladder endometriosis in a 35-year-old woman. Sagittal transvaginal US image obtained after bowel preparation shows an endometriotic nodule (arrows) attached to the bladder wall. The nodule is hypoechogenic and is located in the posterior bladder dome. Note that a small amount of urine is sufficient to help identify the lesion.

Imaging Findings

Anterior Compartment

Anterior lesions are generally separated into two main types: infiltrative nodules attached to the posterior bladder wall, and endometriotic tissue infiltrating the anterior uterine serosa and the round ligaments (Fig 6).

Bladder Wall.—Bladder endometriosis is uncommon and is usually associated with endometriosis elsewhere in the pelvis. In most cases it is asymptomatic, but it may be present in women with suprapubic pain, dysuria, or hematuria (1). Lesions associated with bladder endometriosis are composed of hypoechogenic nodules with irregular contours and well-defined margins; these lesions typically adhere to the posterior bladder dome at the midline (Fig 7). They can be confined to the serosal surface or infiltrate the muscle layer and project into the bladder lumen. The lesions often have a mixed pattern due to the presence of cystic areas, which can be hypoechogenic due to hemorrhagic content. The bladder mucosa is usually intact but may occasionally be ulcerated and bleeding, particularly during menses.

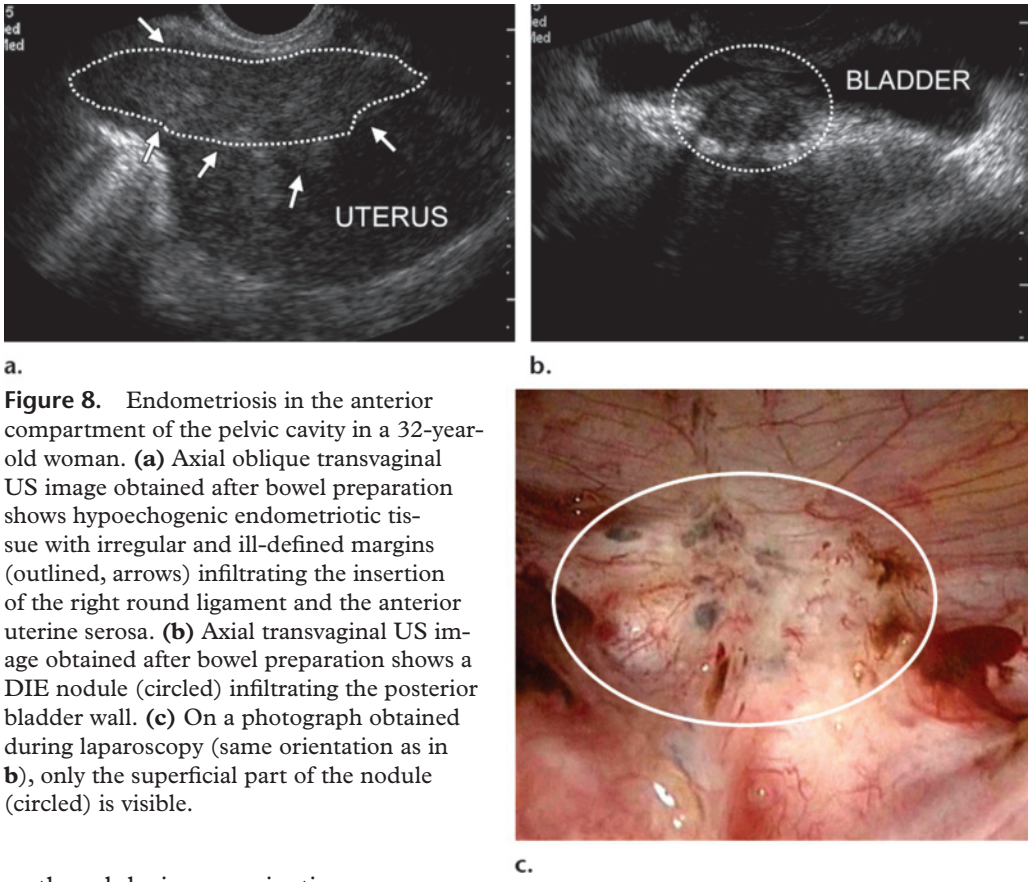

Figure 8. Endometriosis in the anterior compartment of the pelvic cavity in a 32-year-old woman. **(a)** Axial oblique transvaginal US image obtained after bowel preparation shows hypoechogenic endometriotic tissue with irregular and ill-defined margins (outlined, arrows) infiltrating the insertion of the right round ligament and the anterior uterine serosa. **(b)** Axial transvaginal US image obtained after bowel preparation shows a DIE nodule (circled) infiltrating the posterior bladder wall. **(c)** On a photograph obtained during laparoscopy (same orientation as in **b**), only the superficial part of the nodule (circled) is visible.

The information gathered during examination should include the diameter of the nodules and, whenever possible, the degree of infiltration into the bladder wall. Vesical filling plays an important role in this context, and a small amount of urine is necessary to display the posterior vesical wall. The differential diagnosis for bladder lesions includes a urachal remnant, which is seen in 32% of healthy adults. A urachal remnant typically manifests as focal hypoechogenic thickening of the anterior bladder wall at the midline and generally contains a small anechoic cyst (22). The main difference between a urachal remnant and an endometriotic nodule is that the former has an anterior location adjacent to the anterior abdominal wall, whereas the latter has a posterior location. Epithelial and mesenchymal tumors such as hemangioma, fibroma, and leiomyoma, which grow in the muscular layer (detrusor), are also included in the differential diagnosis (15).

At laparoscopy, vesical DIE lesions usually appear as irregularly shaped whitish nodules containing small hemorrhagic cystic formations with a retractile outward form. The palpation of these lesions with surgical probes reveals irregular, ill-defined, firm nodules. Frequently, only a fraction of the DIE lesions in a patient are accessible with laparoscopy, thus limiting the surgeon´s understanding of the degree to which the lesions have infiltrated the layers of the urinary bladder. Similar to the tip of an iceberg, only a small portion of a nodular endometriotic lesion is visible, a fact that emphasizes the importance of a detailed preoperative US evaluation.

Uterine Serosa.—Lesions that compromise the anterior uterine serosa have an infiltrative pattern with indistinct margins, generally with plaquelike rather than nodular morphologic features. The tissue is hypoechogenic relative to the myometrium but not relative to bladder lesions, and usually has multiple bright foci or small cystic areas (Figs 8, 9). The uterine insertion of the round ligaments is frequently affected, and sometimes the lesion (if nodular) resembles a subserosal leiomyoma. Retractile margins and the presence of small cystic areas or bright foci aid in making the diagnosis, which nevertheless can sometimes be difficult.

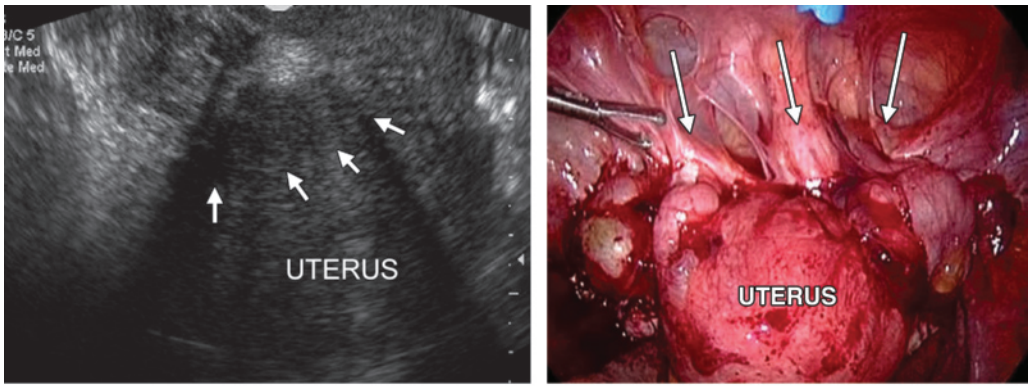

a. b.

Figure 9. Extensive DIE lesions in the anterior compartment of the pelvic cavity in a 30-year-old woman. **(a)** Sagittal transvaginal US image obtained after bowel preparation shows heterogeneous hypoechogenic tissue with ill-defined margins (arrows) occupying the space between the uterus and bladder. **(b)** Photograph obtained during laparoscopy shows an extensive endometriotic mass (arrows) in the anterior compartment that adheres firmly to the anterior peritoneal wall and uterine serosa. The uterus is displaced posteriorly.

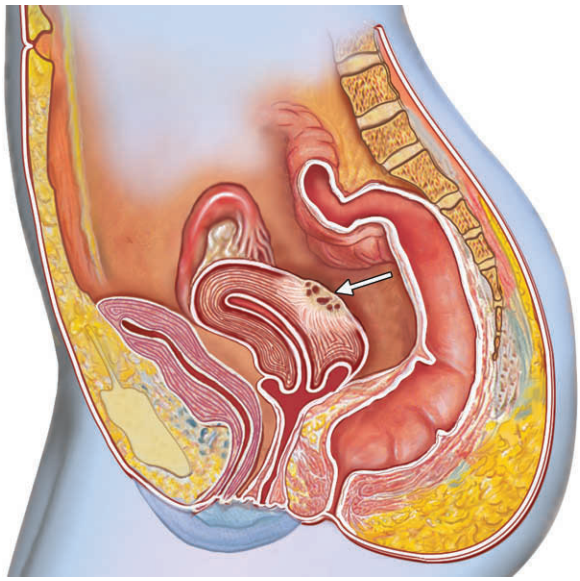

Figure 10. Drawing (midsagittal view) of the female pelvis shows endometriotic tissue (arrow) infiltrating the posterior uterine serosa.

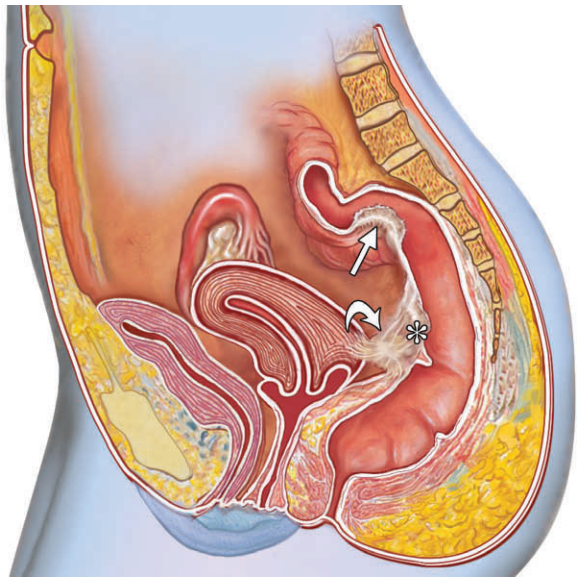

Figure 11. Drawing (midsagittal view) of the female pelvis shows DIE lesions compromising the rectosigmoid transition (straight arrow), rectal wall (*), and retrocervical area (curved arrow). The latter adheres to the rectal lesion, obliterating the pouch of Douglas.

At laparoscopy, these lesions can vary from small areas of tissue distortion with red hemorrhagic spots to large masses associated with firm adhesions that may resemble uterine adenomyosis.

Posterior Compartment

The posterior compartment is frequently affected by DIE, which is classified according to the site affected, whether *(a)* the retrocervical space and rectovaginal area, *(b)* the rectosigmoid colon, or *(c)* the posterior vaginal fornix.

Retrocervical Space and Rectovaginal Area.— The retrocervical region is the site most commonly affected by DIE, usually in association with involvement of the pouch of Douglas (Figs 10, 11) (20). DIE lesions can have a variety of

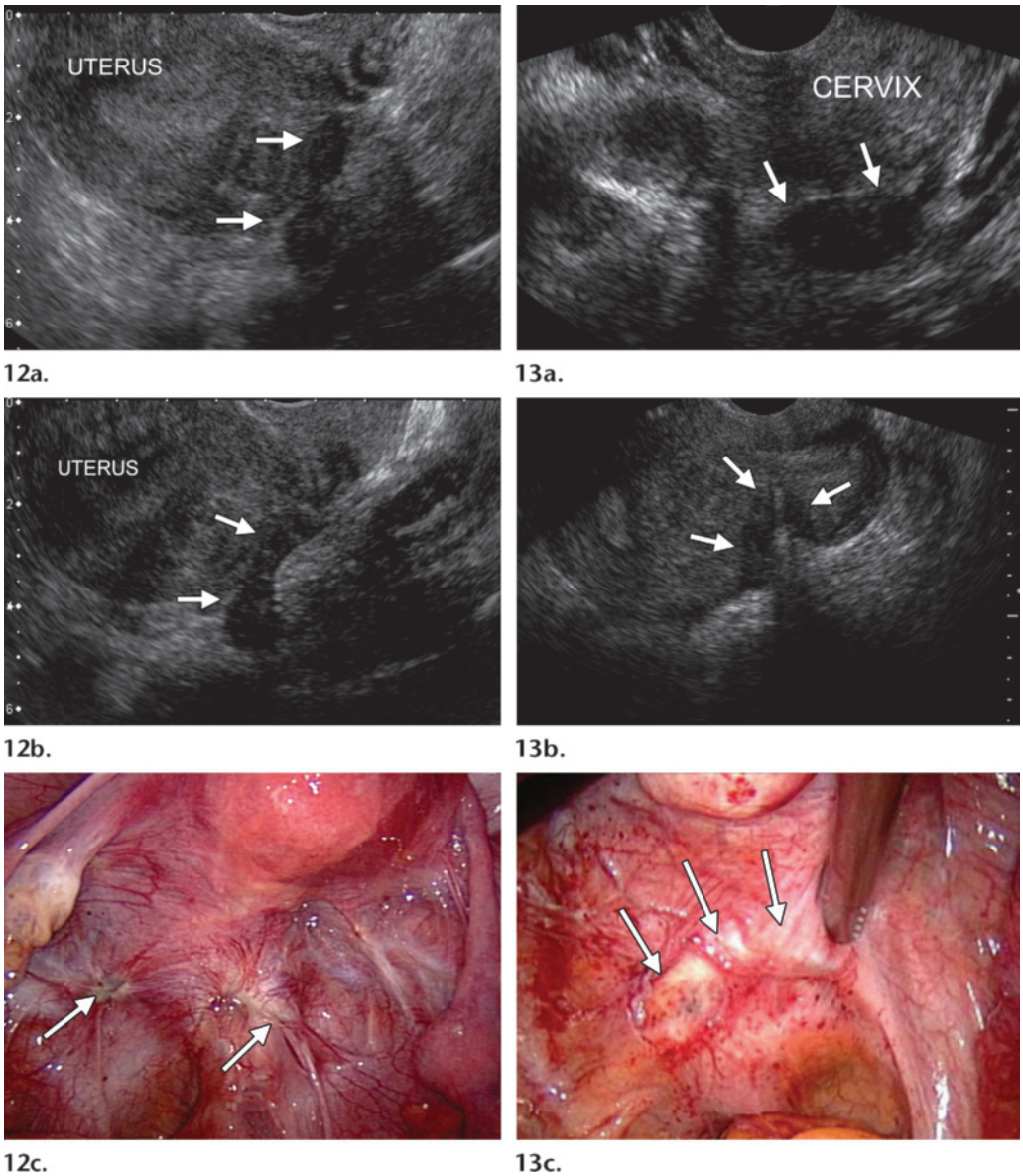

Figures 12, 13. **(12)** DIE compromising the USLs in a 34-year-old woman. **(a, b)** Midparasagittal transvaginal US images obtained after bowel preparation show hypoechogenic nodules (arrows) at the insertion of the right **(a)** and left **(b)** USLs. **(c)** Photograph of the posterior compartment obtained during laparoscopy shows DIE lesions in both USLs (arrows). **(13)** Endometriotic lesions in a 39-year-old woman. **(a)** Sagittal oblique transvaginal US image obtained after bowel preparation shows an oval hypoechogenic nodule with well-defined contours in the left USL (arrows). **(b)** Sagittal transvaginal US image obtained after bowel preparation shows hypoechogenic retractile tissue (arrows) infiltrating the uterine torus. **(c)** Photograph obtained during laparoscopy shows endometriotic lesions (arrows) compromising the left USL and the uterine torus.

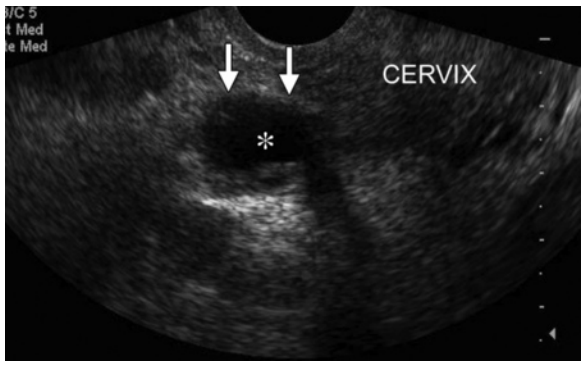

Figure 14. Mixed endometriotic nodule in a 29-year-old woman. Axial oblique transvaginal US image obtained after bowel preparation shows a mixed endometriotic nodule (arrows) in the right USL. Note the cystic area within the nodule (*).

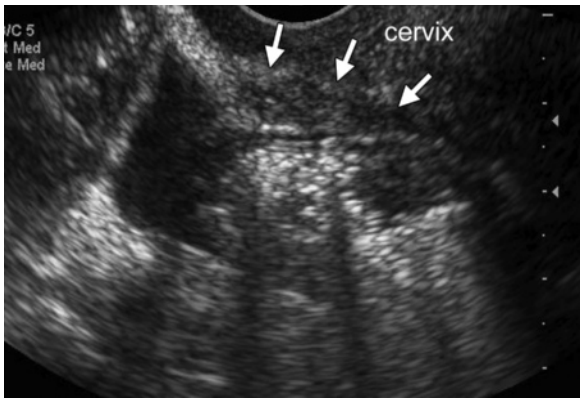

Figure 15. Endometriotic nodule with hypoechogenic thickening in a 31-year-old woman. Axial oblique transvaginal US image obtained at the level of the uterine cervix after bowel preparation shows an endometriotic nodule (arrows) in the right USL. The ligament is thickened and hypoechogenic.

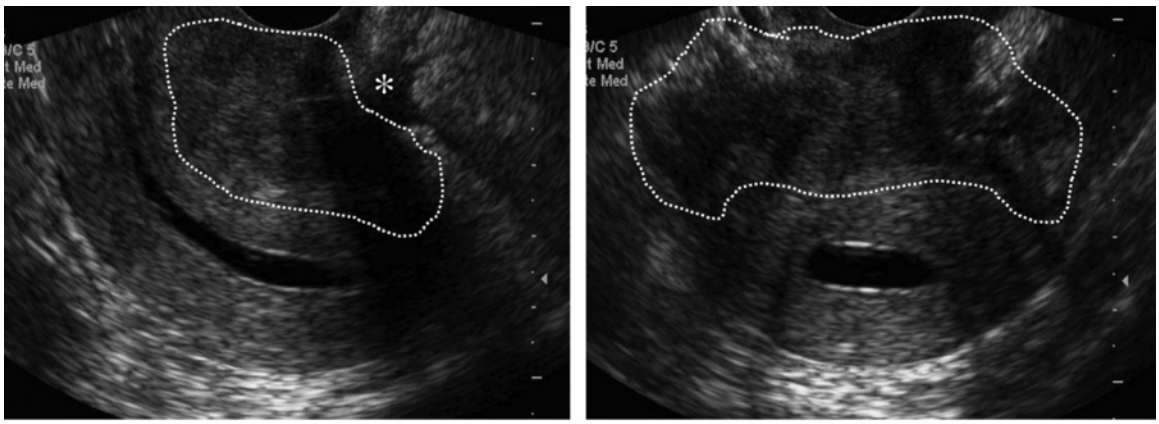

a. **b.**

Figure 16. DIE in a 31-year-old woman with a retroflexed uterus. Sagittal **(a)** and axial **(b)** transvaginal US images obtained after bowel preparation show hypoechogenic endometriotic tissue with irregular and ill-defined margins (outlined) infiltrating the posterior uterine serosa. There is also an endometriotic nodule infiltrating the rectal wall (* in **a**) that adheres to the retrouterine lesion. The uterine cavity is somewhat distended due to previous hysterosonography.

appearances, including *(a)* hypoechogenic nodules with regular or irregular margins (Figs 12, 13); *(b)* mixed nodules due to cystic areas with hemorrhagic content (Fig 14); *(c)* hypoechogenic thickening with regular or irregular margins near the site of cervical USL insertion (Fig 15); and *(d)* infiltrating hypoechogenic tissue with indistinct margins that covers the posterior uterine serosa, usually from the uterine fundus to the isthmus, frequently in association with retractile retroflexion of the uterus (Fig 16). As in the anterior compartment, the latter pattern can include multiple bright foci or small cystic areas. In patients with a retroflexed uterus, evaluation of the retrocervical region can be difficult, either because the uterine corpus impairs visualization of the USL insertion (Fig 17) or due to pain in the pubic region caused by the angulation of the probe that is required to assess this area.

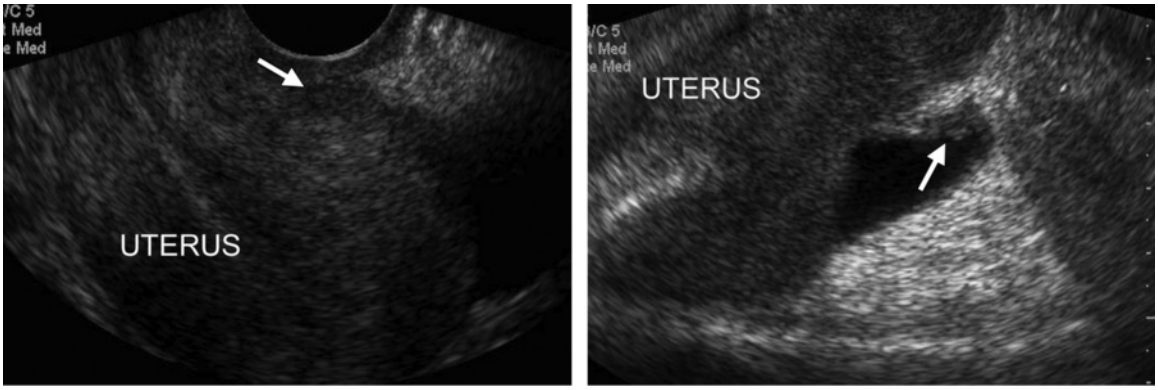

a. b.

Figure 17. Retrocervical endometriosis in a 30-year-old woman. The patient was undergoing ovulation monitoring. **(a)** On a sagittal transvaginal US image obtained on day 13 of the menstrual cycle after bowel preparation, the retroflexion of the uterine fundus impairs visualization of the retrocervical space, but hypoechogenic thickening is suspected (arrow). **(b)** On a sagittal transvaginal US image obtained on day 16 of the menstrual cycle, the uterus is anteflexed, and a small amount of postovulatory fluid allows better identification of the retrocervical lesion (arrow).

The differential diagnosis includes peritoneal metastasis, most commonly from gastrointestinal and ovarian malignancies (23). The metastatic implants can mimic endometriotic lesions when located in gravity-dependent recesses of the peritoneum, such as the pouch of Douglas and the retrocervical space. In general, tumor nodules have a round shape compared with DIE lesions; in addition, they show increased vascularity at color Doppler US. Ascites is a finding that frequently accompanies peritoneal carcinomatosis. Differentiation can be difficult at times, but the presence of an associated tumor elsewhere in the abdominal cavity aids in making the final diagnosis.

In the absence of extensive adhesions, retrocervical DIE lesions are easily identified at laparoscopy. Irregular pale thickening and nodularity of USLs with irregular margins characterize most lesions.

Rectovaginal lesions are frequently an inferior extension of retrocervical and posterior vaginal lesions (1). They can be palpable as firm nodules at clinical examination. These lesions appear similar to retrocervical nodules at imaging, and their presence on the rectal wall should be evaluated due to the proximity of the nodules to the intestinal serosa (Fig 18).

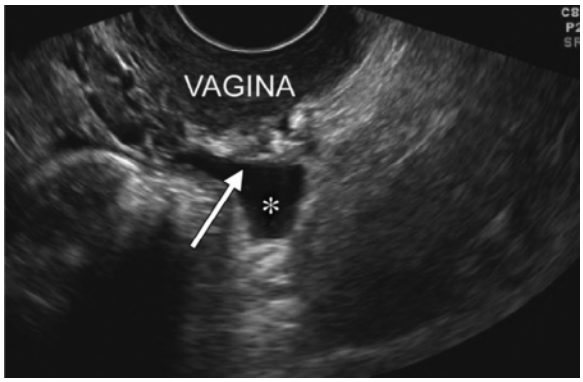

Figure 18. Retrovaginal lesion in a 28-year-old woman. Sagittal transvaginal US image obtained after bowel preparation shows a mixed endometriotic nodule (arrow) in the rectovaginal area. The lesion exhibits small cystic areas and punctate bright foci and is affixed to the posterior vaginal wall. Note that a small amount of fluid in the pouch of Douglas (*) delineates the posterior peritoneal reflection. The rectal wall is normal.

These lesions have a laparoscopic appearance similar to that of lesions observed in the bladder and, therefore, are not readily accessible at endoscopy. Careful instrumental palpation of the compromised area, along with incision of the posterior cul-de-sac peritoneum, exposes DIE lesions.

Rectosigmoid Colon.—Intestinal endometriosis has been observed in 37% of women with DIE

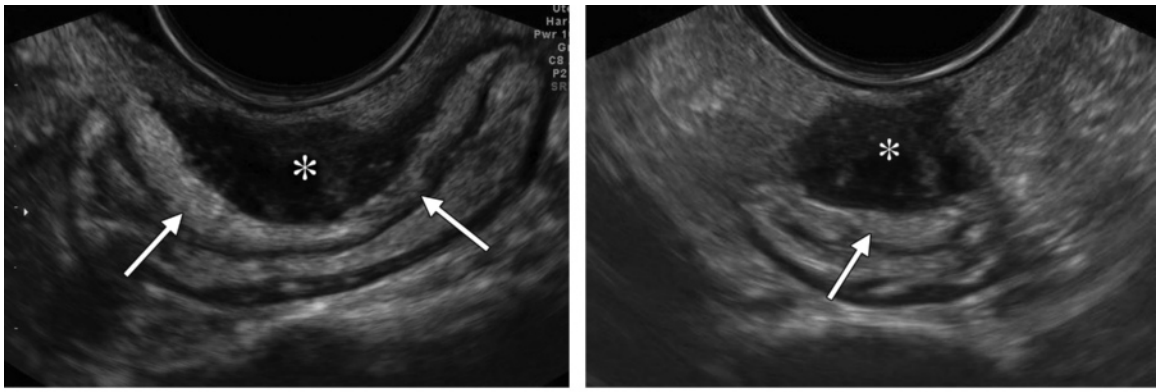

a. b.

Figure 19. Rectal lesion in a 33-year-old woman. Sagittal **(a)** and axial **(b)** transvaginal US images obtained after bowel preparation show a DIE lesion (*) attached to the rectal wall. The nodule is hypoechogenic and infiltrates the bowel wall to the internal muscularis propria. The hyperechogenic submucosa is intact (arrows).

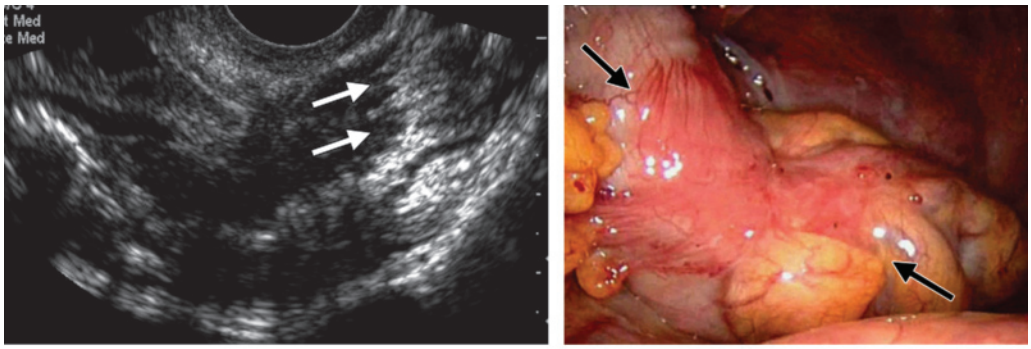

a. b.

Figure 20. Sigmoid lesion in a 35-year-old woman. Sagittal transvaginal US image obtained after bowel preparation **(a)** and photograph obtained during laparoscopy **(b)** show an endometriotic lesion attached to the sigmoid colon. The US image depicts the nodule infiltrating the muscularis propria and the submucosa, which has a striated aspect (arrows in **a**), whereas the photograph shows only serosal involvement (arrows in **b**).

and is present in several of the following regions (in descending order of frequency): the rectum and sigmoid colon, the appendix, the terminal ileum, and the cecum (1). Symptoms of this condition, alone or in combination, include acute or chronic abdominal pain, diarrhea, constipation, and hematochezia (24). At clinical examination, intestinal endometriosis can mimic many different conditions; however, the observation that its symptoms frequently occur around the time of menstruation can aid in making the correct diagnosis.

Rectosigmoid lesions manifest as hypoechogenic nodules with obtuse margins that are attached to the intestinal wall, causing retraction of the C-shaped segment of the colon and extrinsic compression of the bowel. In the axial plane, rectal lesions have a typical pyramidal shape, with the base adhering to the anterior rectal wall and the apex oriented toward the retrocervical space (Fig 19). In most cases, intestinal lesions are confined to the serosa or muscularis propria, and, in contrast to lesions in other pelvic sites, are almost always homogeneous and rarely contain cystic areas. If the lesions involve the submucosa, they generally appear as a striated aspect of the hyperechogenic layer (Fig 20). Gross examination

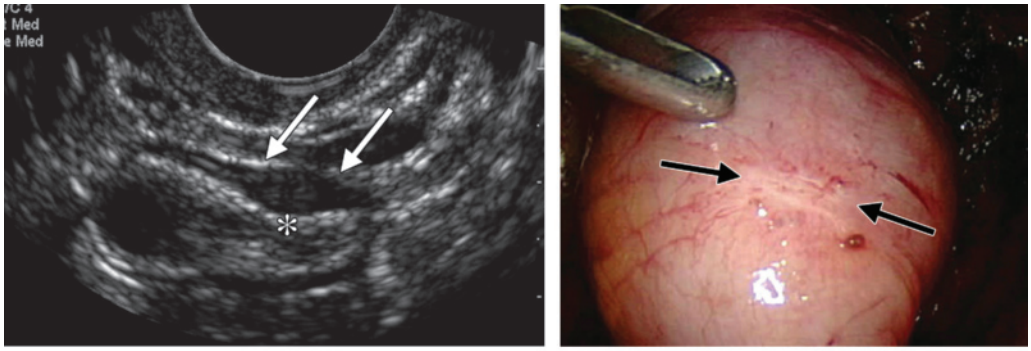

a. b.

Figure 21. Endometriotic nodule in a 28-year-old woman. **(a)** Axial transvaginal US image obtained after bowel preparation shows a small, 8-mm endometriotic nodule (arrows) that infiltrates the rectal wall and reaches the internal muscularis propria. The hyperechogenic submucosa (*) is preserved. **(b)** Photograph obtained during laparoscopy shows only serosal involvement by the lesion (arrows).

Figure 22. Endometriotic lesion in a 33-year-old woman. Transabdominal US image obtained with a linear transducer shows a hypoechogenic endometriotic lesion (arrows) attached to the descending colon. The submucosa surrounding the lesion is intact (*).

of this bowel segment reveals that it is hardened and often angulated by a poorly defined, usually irregularly shaped mural mass that is firm, gray-white, and solid. The bulk of this mass is represented by markedly thickened muscularis propria. The overlying mucosa is intact, unlike in primary adenocarcinoma (1). Rectal nodules frequently adhere to retrocervical lesions and obliterate the pouch of Douglas. Importantly, transvaginal US performed after bowel preparation allows examination of the entire rectosigmoid colon in the majority of patients, which may lead to the identification of multiple lesions. Furthermore, transvaginal US performed after bowel preparation permits high-spatial-resolution dynamic evaluation of the bowel in both the sagittal and axial planes, which is crucial to visualizing small and laterally located lesions (Fig 21). Transabdominal evaluation with a linear transducer can depict nodules in the descending colon and ileocecal region, since these segments are superficially located in the abdominal cavity (Fig 22). In obese patients, this access can be limited.

Occasionally, factors other than gas and residues can impair the identification of intestinal lesions (eg, large ovarian cysts, uterine fibroids) situated between the transvaginal transducer and the bowel segment being evaluated. In addition, attention should be paid to the US interface caused by the intestinal folds, which can mimic an endometriotic lesion. Rotation of the probe can help eliminate this artifact.

The differential diagnosis includes colon carcinoma and peritoneal metastatic disease (23,25). Carcinoma of the colon originates at the mucosa, unlike endometriosis, which compromises the intestinal wall from the external layer into the internal layer.

The appearance of intestinal lesions at laparoscopy is localized to the loop compromised

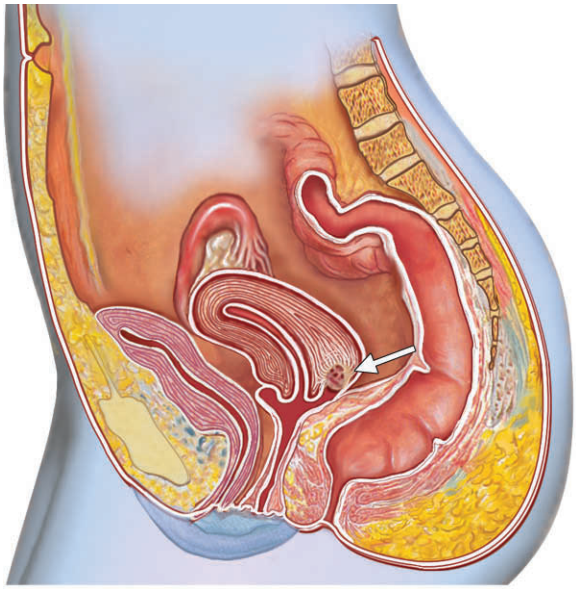

23.

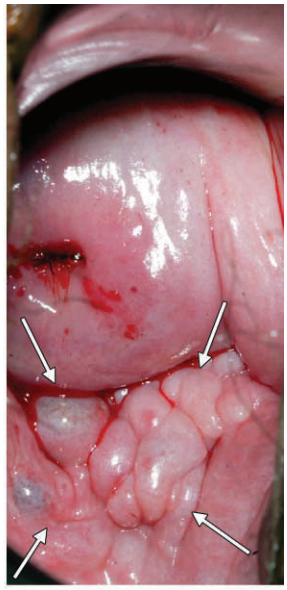

24.

Figures 23, 24. **(23)** Illustration (midsagittal view) of the female pelvis depicts a mixed endometriotic lesion (arrow) obliterating the posterior vaginal fornix. **(24)** Photograph obtained during speculum examination of the vagina shows endometriotic tissue (arrows) obliterating the posterior vaginal fornix.

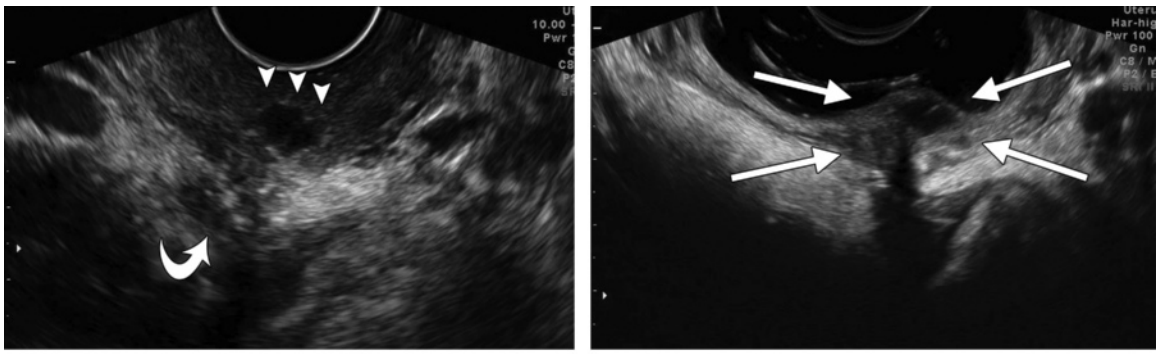

a. b.

Figure 25. Retrocervical-vaginal endometriosis in a 27-year-old woman. **(a)** Axial transvaginal US image obtained after bowel preparation shows a retrocervical nodule (arrow) attached to the posterior vaginal wall. The nodule has a heterogeneous appearance and ill-defined hypoechogenic thickness. A cyst is also noted (arrowheads). **(b)** Axial transvaginal US image, obtained after the application of gel to distend the posterior vaginal fornix, more clearly depicts the vaginal lesion (arrows).

by endometriosis and consists of a thick parietal structure surrounding a central depression and distorting the affected segment. The depth of the intestinal wall infiltration cannot be assessed with laparoscopy. Once again, knowledge of US peculiarities enhances the surgeon´s approach and surgical efficacy.

Posterior Vaginal Fornix.—Vaginal DIE is common and is frequently associated with DIE in other pelvic sites, especially the retrocervical space (Figs 23, 24) (1). Symptoms such as dyspareunia and chronic pelvic pain are usually reported, and painful nodules can be assessed with clinical and speculum examination. Vaginal DIE lesions can appear as *(a)* hypoechogenic nodules, with either regular or irregular margins and containing small cystic areas or punctuate bright foci, that infiltrate the posterior vaginal wall either medially or laterally (Fig 25); and *(b)* hypoechogenic thickening of the superior third of the posterior vaginal wall with an irregular

contour but no defined nodule (Fig 26). Insertion of US gel into the upper vaginal canal during transvaginal US performed after bowel preparation is useful in delineating the interface between the posterior cervical lip and the vaginal wall, and in showing the nodules protruding into the posterior vaginal fornix (Fig 25) (26). The probe is positioned in the middle third of the vagina and is moved up and down.

Other Pelvic Sites

DIE lesions can be observed in other locations in the pelvic cavity, such as the terminal ileum, appendix, and pelvic ureters. Appendiceal and ileal lesions have morphologic features that are quite similar to those of rectosigmoid lesions, manifesting as hypoechogenic solid nodules attached to the intestinal wall with different degrees of infiltration. They can be assessed with transvaginal US performed after bowel preparation if they are located in the pelvic cavity, or, because these lesions may be inaccessible via a transvaginal route, a transabdominal approach with a linear transducer can be adopted.

Paracervical nodular lesions greater than 2 cm in diameter may indicate that ureteral lesions are also present. Ureteral endometriosis is uncommon but can involve the distal pelvic ureters and lead to stricture, resulting in hydronephrosis with silent loss of renal function. Detection of early involvement is challenging due to the lack of sensitive diagnostic tools. Pelvic MR imaging accompanied by a urographic sequence appears to be the most sensitive diagnostic method (27).

Because of the presence of adhesions and the limited accessibility of the ureters, laparoscopic identification of DIE lesions requires an experienced surgeon to resect the adhesions and endometriotic lesions from the ureters.

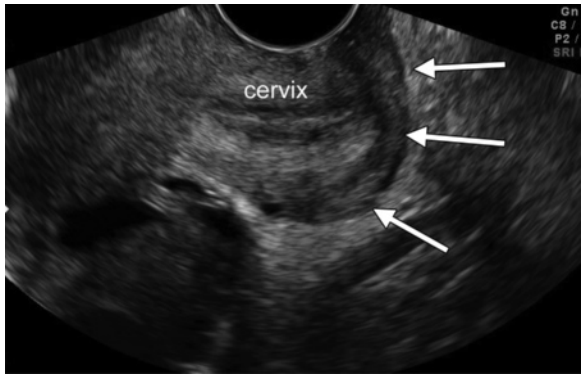

Figure 26. Sagittal transvaginal US image obtained in the cervical plane after bowel preparation shows hypoechogenic thickening of the posterior vaginal wall (arrows) without a defined nodule.

Conclusions

In this article, we have presented our protocol for the use of transvaginal US after bowel preparation in assessing DIE in multiple pelvic sites. The most representative findings of DIE are hypoechogenic nodules throughout the affected sites and thickening of the intestinal wall. Transvaginal US performed after bowel preparation should be the first-line imaging modality for the evaluation of women with suspected endometriosis, thereby contributing to case management, patient counseling, and surgical planning. It is vital that radiologists be familiar with the technique of transvaginal US performed after bowel preparation and with the US patterns of DIE lesions.

Teaching Point

References

1. Clement MD. Diseases of the peritoneum (including endometriosis). 5th ed. New York, NY: Springer-Verlag, 2002; 729–789.
2. Ballard K, Lowton K, Wright J. What's the delay? a qualitative study of women's experiences of reaching a diagnosis of endometriosis. Fertil Steril 2006;86 (5):1296–1301.
3. Fauconnier A, Chapron C. Endometriosis and pelvic pain: epidemiological evidence of the relationship and implications. Hum Reprod Update 2005; 11(6):595–606.

4. Chapron C, Dubuisson JB, Pansini V, et al. Routine clinical examination is not sufficient for diagnosing and locating deeply infiltrating endometriosis. J Am Assoc Gynecol Laparosc 2002;9(2):115–119.
5. Anaf V, Simon P, Fayt I, Noel J. Smooth muscles are frequent components of endometriotic lesions. Hum Reprod 2000;15(4):767–771.
6. Bazot M, Darai E, Hourani R, et al. Deep pelvic endometriosis: MR imaging for diagnosis and prediction of extension of disease. Radiology 2004;232(2): 379–389.
7. Abrao MS, Gonçalves MO, Dias JA Jr, Podgaec S, Chamié LP, Blasbalg R. Comparison between clinical examination, transvaginal sonography and magnetic resonance imaging for the diagnosis of deep endometriosis. Hum Reprod 2007;22(12): 3092–3097.
8. Chamié LP, Blasbalg R, Gonçalves MO, Carvalho FM, Abrão MS, de Oliveira IS. Accuracy of magnetic resonance imaging for diagnosis and preoperative assessment of deeply infiltrating endometriosis. Int J Gynaecol Obstet 2009;106(3):198–201.
9. Goncalves MO, Podgaec S, Dias JA Jr, Gonzalez M, Abrao MS. Transvaginal ultrasonography with bowel preparation is able to predict the number of lesions and rectosigmoid layers affected in cases of deep endometriosis, defining surgical strategy. Hum Reprod 2010;25(3):665–671.
10. Bazot M, Thomassin I, Hourani R, Cortez A, Darai E. Diagnostic accuracy of transvaginal sonography for deep pelvic endometriosis. Ultrasound Obstet Gynecol 2004;24(2):180–185.
11. Hudelist G, Oberwinkler KH, Singer CF, et al. Combination of transvaginal sonography and clinical examination for preoperative diagnosis of pelvic endometriosis. Hum Reprod 2009;24(5):1018–1024.
12. Hudelist G, Tuttlies F, Rauter G, Pucher S, Keckstein J. Can transvaginal sonography predict infiltration depth in patients with deep infiltrating endometriosis of the rectum? Hum Reprod 2009;24(5): 1012–1017.
13. Bazot M, Lafont C, Rouzier R, Roseau G, Thomassin-Naggara I, Daraï E. Diagnostic accuracy of physical examination, transvaginal sonography, rectal endoscopic sonography, and magnetic resonance imaging to diagnose deep infiltrating endometriosis. Fertil Steril 2009;92(6):1825–1833.
14. Donnez J, Spada F, Squifflet J, Nisolle M. Bladder endometriosis must be considered as bladder adenomyosis. Fertil Steril 2000;74(6):1175–1181.
15. Fedele L, Bianchi S, Raffaelli R, Portuese A. Pre-operative assessment of bladder endometriosis. Hum Reprod 1997;12(11):2519–2522.
16. Pereira RM, Zanatta A, de Mello Bianchi PH, Chamié LP, Gonçalves MO, Serafini PC. Transvaginal ultrasound after bowel preparation to assist surgical planning for bowel endometriosis resection. Int J Gynaecol Obstet 2009;104(2):161.
17. Valenzano Menada M, Remorgida V, Abbamonte LH, Nicoletti A, Ragni N, Ferrero S. Does transvaginal ultrasonography combined with water-contrast in the rectum aid in the diagnosis of rectovaginal endometriosis infiltrating the bowel? Hum Reprod 2008;23(5):1069–1075.
18. Goncalves MO, Dias JA Jr, Podgaec S, Averbach M, Abrão MS. Transvaginal ultrasound for diagnosis of deeply infiltrating endometriosis. Int J Gynaecol Obstet 2009;104(2):156–160.
19. Kinkel K, Chapron C, Balleyguier C, Fritel X, Dubuisson JB, Moreau JF. Magnetic resonance imaging characteristics of deep endometriosis. Hum Reprod 1999;14(4):1080–1086.
20. Chapron C, Fauconnier A, Vieira M, et al. Anatomical distribution of deeply infiltrating endometriosis: surgical implications and proposition for a classification. Hum Reprod 2003;18(1):157–161.
21. Jenkins S, Olive DL, Haney AF. Endometriosis: pathogenetic implications of the anatomic distribution. Obstet Gynecol 1986;67(3):335–338.
22. Yu JS, Kim KW, Lee HJ, Lee YJ, Yoon CS, Kim MJ. Urachal remnant diseases: spectrum of CT and US findings. RadioGraphics 2001;21(2):451–461.
23. Levy AD, Shaw JC, Sobin LH. Secondary tumors and tumorlike lesions of the peritoneal cavity: imaging features with pathologic correlation. RadioGraphics 2009;29(2):347–373.
24. Remorgida V, Ferrero S, Fulcheri E, Ragni N, Martin DC. Bowel endometriosis: presentation, diagnosis, and treatment. Obstet Gynecol Surv 2007;62(7): 461–470.
25. Woodward PJ, Sohaey R, Mezzetti TP Jr. Endometriosis: radiologic-pathologic correlation. RadioGraphics 2001;21(1):193–216.
26. Dessole S, Farina M, Rubattu G, Cosmi E, Ambrosini G, Nardelli GB. Sonovaginography is a new technique for assessing rectovaginal endometriosis. Fertil Steril 2003;79(4):1023–1027.
27. Seracchioli R, Mabrouk M, Manuzzi L, et al. Importance of retroperitoneal ureteric evaluation in cases of deep infiltrating endometriosis. J Minim Invasive Gynecol 2008;15(4):435–439.

RadioGraphics

Transvaginal US after Bowel Preparation for Deeply Infiltrating Endometriosis: Protocol, Imaging Appearances, and Laparoscopic Correlation

Luciana Pardini Chamié, MD, PhD • Ricardo Mendes Alves Pereira, MD Alysson Zanatta, MD • Paulo Cesar Serafini, MD, PhD

RadioGraphics 2010; 30:1235–1249 • **Published online** 10.1148/rg.305095221 • **Content Codes:** GU OB US

Page 1236
Transvaginal US is a more accessible and widespread method of pelvic imaging and is the initial imaging modality for evaluating patients with suspected endometriosis (10,11).

Page 1237
Bowel preparation is used to eliminate fecal residues and gas in the rectosigmoid colon (Fig 1) and is accomplished by administering *(a)* a mild laxative orally at 8:00 AM and 2:00 PM the day before the transvaginal US examination, *(b)* a low-residue diet on the day before and the day of the examination, and *(c)* a rectal enema consisting of 120 mL of sodium diphosphate approximately 1 hour prior to the examination.

Page 1237
After bowel preparation, transvaginal US is performed with a 5–9-MHz transducer. It is used to evaluate the uterus and ovaries as well as the pelvic peritoneum, which includes the bladder, vesicouterine pouch, pouch of Douglas, retrocervical space, rectovaginal septum, and posterior vaginal fornix.

Page 1238 (Figure on page 1238)
It is important that the examiner have a knowledge of the normal appearance of the intestinal wall at transvaginal US performed after bowel preparation. The bowel wall is composed of different layers, each of which has a typical appearance at this imaging modality. These layers include the serosa (thin hyperechoic line), the muscularis propria (two hypoechoic strips separated by a thin hyperechoic line), the submucosa (hyperechoic), the muscularis mucosa (hypoechoic), and the interface between the lumen and the mucosal layer (hyperechoic) (Fig 4).

Page 1248
The most representative findings of DIE are hypoechogenic nodules throughout the affected sites and thickening of the intestinal wall.